

P-26 – Prof. Dr. Woong Ju, et al - Oncothermia in Gynecologic Oncology (Experience of the EWHA Womans University Hospital, Seoul)



Oncothermia in Gynecologic Oncology

Woong Ju MD, Seung Cheol Kim MD

Department of Obstetrics & Gynecology, College of Medicine Ewha Womans University, Mok-Dong Hospital, Seoul Korea(South)

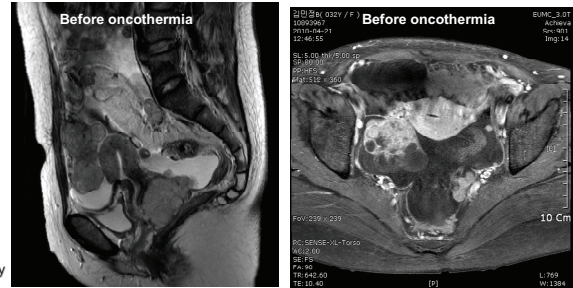
Objective

Ewha Womans Hospital intensively uses oncothermia for gynecological malignancies. The time for the application of the new technology is not enough to present statistically evaluable number of patients in cohorts, so our objective is reporting only an interesting case, having multiple primer metastases.

Method

We apply for the treatment the EHY-2000 oncothermia device with variable electrode sizes. A treatment cycle contains 10 sessions in average, made 2-3 times a week, having at least a day between the treatments. Every session was performed in duration of 60 min. Patients of advanced uterine cervix and ovary tumors are treated. Oncothermia was applied complementary to various chemotherapies.

The case which we show is advanced patient (EOv, 32 y), diagnosed in April of this year. Past history was three years ago a cesarean section, with medical history: DM/HTN/Tb/Hepatitis (-/-/-). No family history was registered. The uterine cervix punch biopsy was positive: adenocarcinoma, as well as the cytology of the ascetic fluid was also positive for adenocarcinoma. The images (CT, MRI, PET) show large ovarian mass, suspected double primary cancer (uterine cervix and ovary). The peritoneum had serious ascites, (probable carcinomatosis peritonei with unilateral Krukenberg disease). From April to June was treated with oncothermia and three times with neoadjuvant chemotherapy (Genexol+ Carboplatin). Patient was operated in August. Uterine cervical mass and bilateral, ovarian mass - invasion to vagina and peritoneum DDx). Primary uterine cervix cancer with carcinomatosis peritonei with bilateral Krukenberg disease. Double primary cancer of uterine, cervix and both ovary with carcinomatosis peritonei

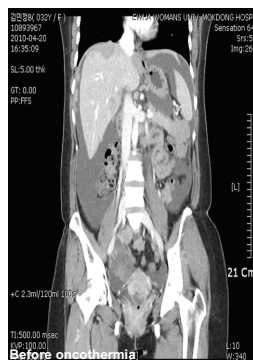

Results

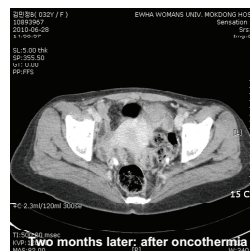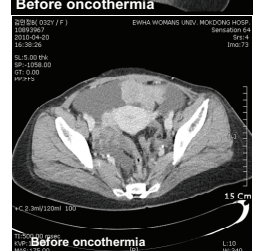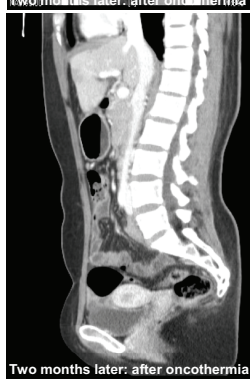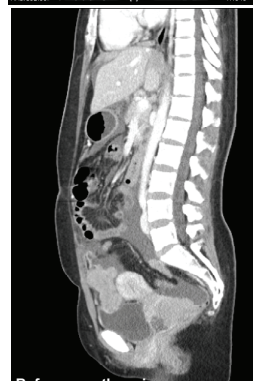
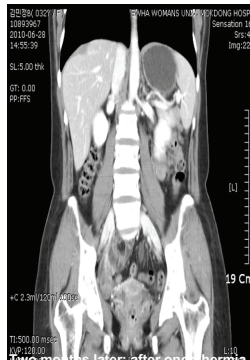Diagnosis in June shows curative improvement: Decreased extent of mass in uterine cervix and in right ovary. Improvement of hepatic metastasis in both lobes of the liver with residual lesion.

Improvement of peritoneal carcinomatosis with residual lesion. PET shows impressive improvement of cure. The operative results in August showed the pelvic cavity with a vengeance 4*3*3 cm3 a nodular mass with a thick wall of the right ovary was observed in peritoneum, omentum, rectal serosa findings necrotic nodular mass. Abnormalities are not visible on the left ovary. The CA-125 and CA-19-9 tumor-markers had been normalized.

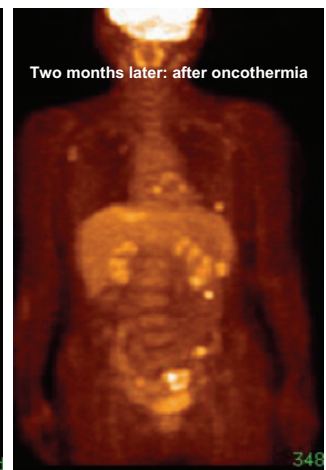
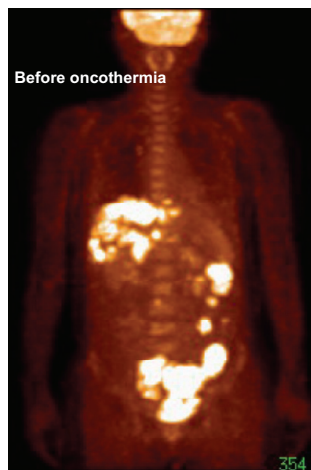Before oncothermia treatment



After oncothermia treatment



Positron Emission Tomography (PET)



Conclusion

Oncothermia treatment is looks feasible to treat advanced gynecologic malignancies. For evidences perspective, randomized studies, and measuring the overall survival as end point is desired.